



PRESENTING CLINICAL SIGNS

History: Grade 2/6 murmur.

DATE

8/19/22

ECHOCARDIOGRAPHIC FINDINGS

2D, M-mode, and Doppler study.

PERFORMED BY:

Sarah Pender, CVT

INTERPRETED BY

Keith Blass, DVM,
MS, DACVIM
(Cardiology)

Left atrial size is normal. The mitral valve leaflets are mildly thickened, and a mild jet of eccentric mitral regurgitation is present. Left ventricular dimensions are normal. Left ventricular systolic function is normal. The aorta and aortic valve are normal. Right atrial and right ventricular dimensions are normal. The tricuspid valve leaflets are mildly thickened, and a mild jet of tricuspid regurgitation is present. TR velocity does not suggest the presence of pulmonary hypertension. The pulmonary artery and pulmonic valve are normal. No shunting lesions are visualized. No heartworms are visualized. No pericardial effusion or cardiac masses are seen.

PATIENT

Jaxon Black

LA - 33.7 mm
LVIDd - 32.2 mm
LVIDs - 21.6 mm
FS - 32%
RA - 17.4 mm
LVOT - 1.65 m/s
RVOT - 1.33 m/s
TR - 2.40 m/s

SPECIES

Canine

BREED

Cocker Spaniel

ASSESSMENT/RECOMMENDATIONS

Degenerative mitral and tricuspid valve disease

This examination demonstrates mild regurgitation of blood across Jaxon's mitral and tricuspid valves resulting from degenerative valve disease. The hemodynamic effects of each of the regurgitations also appear to be mild, as Jaxon does not have secondary dilation of any of his cardiac chambers, and his ventricular systolic function is normal. As such, Jaxon's valvular diseases appear to be well-compensated, and his current risk for the development of clinical signs secondary to them, such as coughing, exercise intolerance, syncope, abdominal distension, and labored breathing, appears to be low.

SEX

No therapy is recommended at this stage of Jaxon's valvular diseases.

MN

A recheck echocardiogram is recommended in 6 months to monitor for disease progression.

AGE

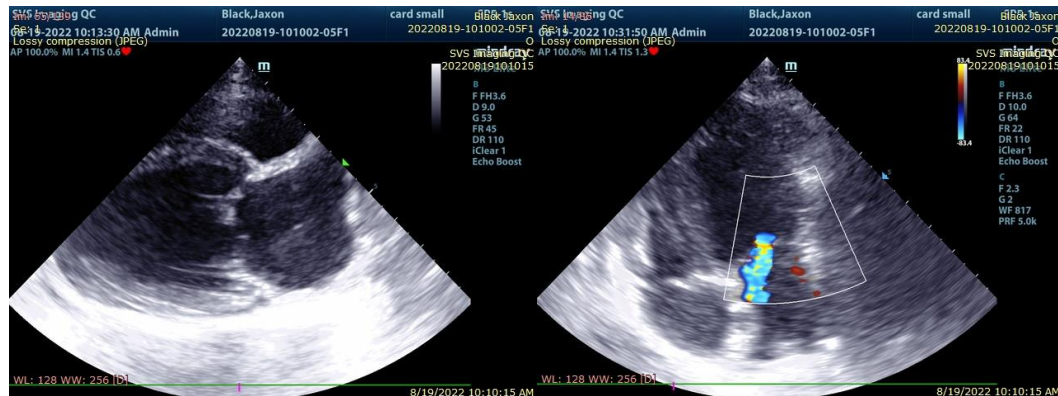7 y

WEIGHT

32 lb

HOSPITAL NAME

SVS Imaging QC



REFERRING VET

Dr. Hook



DATE

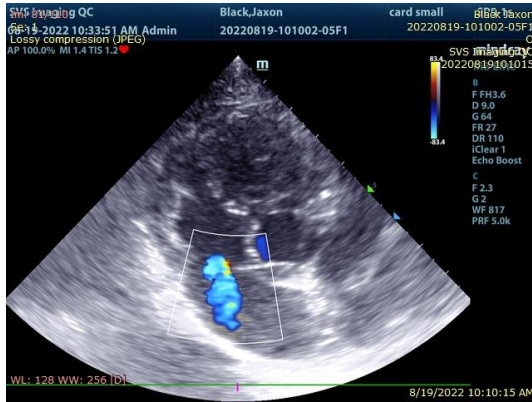
8/19/22

PERFORMED BY:

Sarah Pender, CVT

INTERPRETED BY

Keith Blass, DVM,
MS, DACVIM
(Cardiology)



The information and recommendations provided are based on the images presented by the referring veterinarian. No evaluation can be communicated regarding pathology that was not visible in the image/video clips provided.

Thank you for this referral. If the clinical or image interpretation does not parallel your findings or if I can be of any further assistance please contact me.

PATIENT

Jaxon Black

Keith Blass, DVM, MS, DACVIM (Cardiology)
KeithBlass@gmail.com
631-804-5754

SPECIES

Canine

BREED

Cocker Spaniel

SEX

MN

AGE

7 y

WEIGHT

32 lb

HOSPITAL NAME

SVS Imaging QC

REFERRING VET

Dr. Hook